



**NEET PG 2025**

**Ophthalmology**

**Previous Year**

**Questions with**

**Solutions**

**TUTORIALS**

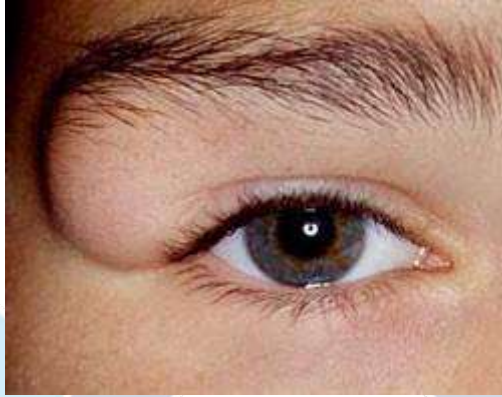
[Click Here to Explore More Ophthalmology PYQs](#)

**OPHTHALMOLOGY – NEET PG 2025**

**Q.1**

**Clinical Question:**

A 15-year-old girl presents with a painless swelling in the right supraorbital region that has been gradually progressing over the past year. What is the most likely diagnosis?



**Options:**

- A) Lacrimal gland mass
- B) Dermoid cyst
- C) Hemangioma
- D) Epidermoid cyst

**Correct Answer: B) Dermoid cyst**

**Q.2**

**Clinical Question:**

A patient presents with guttate lesions in one eye and bullous keratopathy in the other eye. What is the most probable diagnosis?

**Options:**

- A) Trichoma
- B) Herpes keratitis
- C) Fuchs endothelial dystrophy
- D) Keratoconus

**Correct Answer: C) Fuch's endothelial dystrophy**

**Q.3**

**Clinical Question:**

Which of the following statements regarding orbital cellulitis is true?

**Options:**

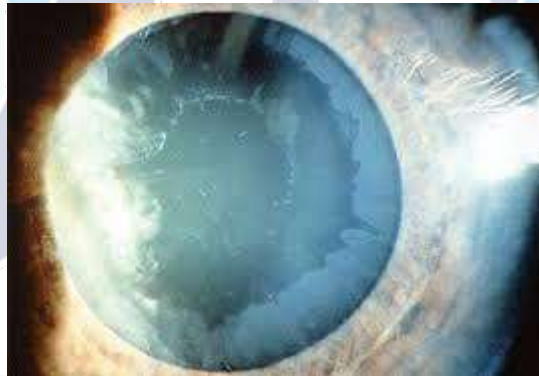- A) Ethmoidal sinusitis is the most common source of infection in all age groups
- B) Topical broad-spectrum antibiotics are the mainstay of treatment
- C) The inflammation is restricted anterior to the orbital wall
- D) Patients characteristically present with proptosis, blurring of vision, normal pupillary and ocular movements

**Correct Answer: A) Ethmoidal sinusitis is the most common source of infection in all age groups**

**Q.4**

**Clinical Question:**

A 65-year-old male presents with complaints of a decrease in vision. There were white deposits on the anterior lens surface, seen during slit lamp examination. What is the most likely diagnosis?



**Options:**

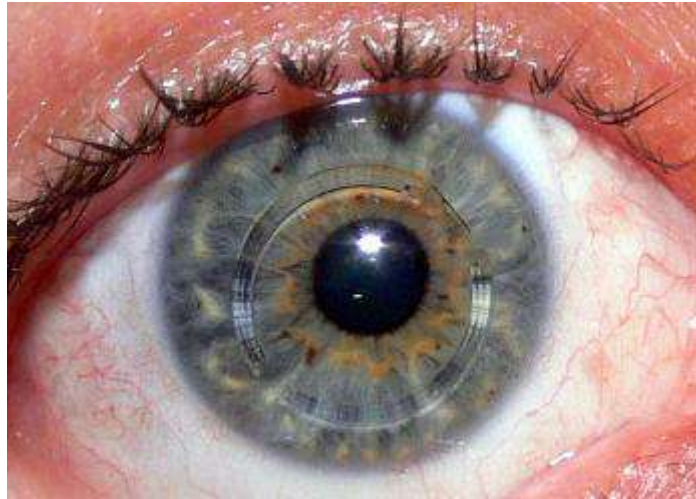
- A) Glaucomflecken with acute angle closure glaucoma
- B) Pseudoexfoliation syndrome
- C) iritis with pupillary deposits
- D) Anterior capsule opacification

**Correct Answer: B) Pseudoexfoliation syndrome**

**Q.5**

**Non-clinical Question:**

Which of the following conditions is treated using the modality shown in the image?



**Options:**

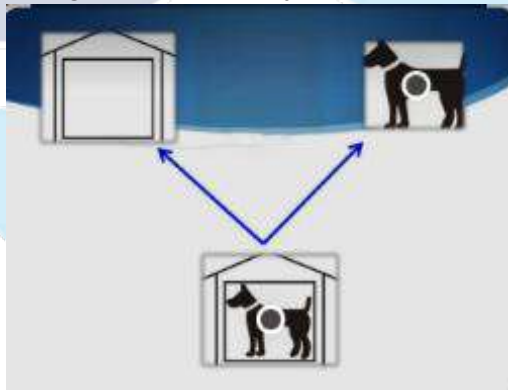
- A) Keratoconus
- B) Keratoglobus
- C) Vogt's limb striae
- D) Corneal dystrophy

**Correct Answer: A) Keratoconus**

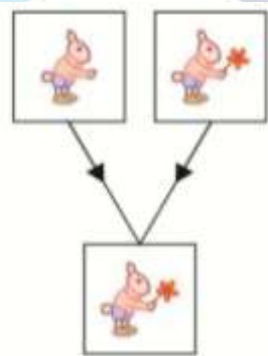
**Q.6**

**Clinical Question:**

Binocular single vision consists of which of the following components, corresponding to Image A and Image B, respectively?



A



B

**Options:**

- A) Fusion and stereopsis
- B) Fusion and simultaneous macular perception
- C) Simultaneous macular perception and stereopsis
- D) Simultaneous macular perception and fusion

**Correct Answer: D) Simultaneous macular perception and fusion**



For more PYQs – Sign up on the DocTutorials App Now!

Website: <https://www.doctutorials.com/plans>

Play store: <https://zcu.io/3jPK>

App store: <https://apple.co/2Zmm9jr>



# TUTORIALS

[Click Here to Explore More Ophthalmology PYQs](#)