



**NEET PG 2025**

**OBG Previous Year  
Questions with  
Solutions**

**TUTORIALS**

[Click Here to Explore More ObGyn PYQs](#)

**OBG – NEET PG 2025**

**Q.1**

**Clinical Question:**

In a woman with a regular 28-day menstrual cycle, which of the following best describes the typical hormonal profile during days 21 to 25 of the cycle?

**Options:**

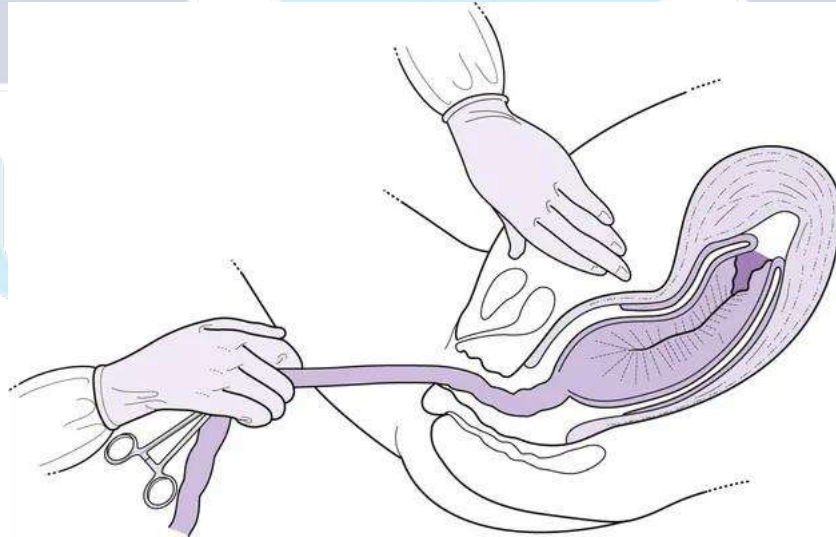
- A) Low estrogen, high progesterone, low LH and FSH
- B) Low estrogen, low progesterone, low FSH and LH
- C) Low estrogen, high progesterone, high FSH and LH
- D) High estrogen, high progesterone, low FSH and LH

**Correct Answer: D) High estrogen, high progesterone, low FSH and LH**

**Q.2**

**Clinical Question:**

Identify the manoeuvre shown in the given image.



**Options:**

- A) Manual removal of placenta
- B) Controlled cord traction
- C) Uterine massage
- D) Bimanual compression of the uterus

[Click Here to Explore More ObGyn PYQs](#)

**Correct Answer: B) Controlled cord traction**

**Q.3**

**Clinical Question:**

A 32-year-old woman with an obstetric score of P2L2 presents with 6 months of secondary amenorrhea. Laboratory evaluation shows FSH 36 mIU/mL, LH 56 mIU/mL, and anti-Müllerian hormone (AMH) 0.05 ng/mL. Which of the following is the most likely diagnosis?

**Options:**

- A) Polycystic Ovarian Syndrome
- B) Primary Ovarian Insufficiency
- C) Hypothyroidism
- D) Hyperprolactinemia

**Correct Answer: B) Primary Ovarian Insufficiency**

**Q.4**

**Clinical Question:**

A 28-year-old woman in labour is undergoing per vaginal examination, and a pulsating umbilical cord is felt below the presenting part. What is the most appropriate next step in management?

**Options:**

- A) Elevate buttocks, push the presenting part upward, and fill the bladder
- B) Attempt to reposition the cord into the vagina and vaginal packing
- C) Wait and watch with close monitoring
- D) Augment labor with oxytocin

**Correct Answer: A) Elevate buttocks, push the presenting part upward, and fill the bladder**

**Q.5**

**Clinical Question:**

A G2P1L1 with a history of a previous cesarean section is undergoing a trial of labor and presents in active labor. During labor, there is fetal bradycardia and maternal tachycardia. Persistent suprapubic pain between contractions is also noted. On examination, the cervix is 8 cm dilated and the vertex is at -1 station. What is the next best step in management?

[Click Here to Explore More ObGyn PYQs](#)

**Options:**

- A) Emergency lower segment cesarean section
- B) Artificial rupture of membranes
- C) Augment labor with oxytocin
- D) Attempt instrumental vaginal delivery

**Correct Answer: A) Emergency lower segment cesarean section**

**Q.6**

**Clinical Question:**

In the repair of a mediolateral episiotomy, what is the correct order of tissue approximation during suturing?

**Options:**

- A) Mucosa → Muscle → Skin
- B) Skin → Mucosa → Muscle
- C) Muscle → Skin → Mucosa
- D) Skin → Muscle → Mucosa

**Correct Answer: A) Mucosa → Muscle →**

**Q.7**

**Clinical Question:**

A patient presents with 2 months of amenorrhea and an enlarged uterus. On examination, there is darkening of the areola, prominent Montgomery's tubercles, a linea nigra is present, and there is bluish discoloration of the vagina on per-vaginal examination. How would you categorize these signs of pregnancy?

**Options:**

- A) Presumptive signs of pregnancy
- B) Probable signs of pregnancy
- C) Positive signs of pregnancy
- D) Diagnostic signs of pregnancy

**Correct Answer: B) Probable signs of pregnancy**

[Click Here to Explore More ObGyn PYQs](#)

**Q.8**

**Clinical Question:**

Hydronephrosis due to the extension of a cervical tumor is a criterion for which FIGO stage of cervical cancer?

**Options:**

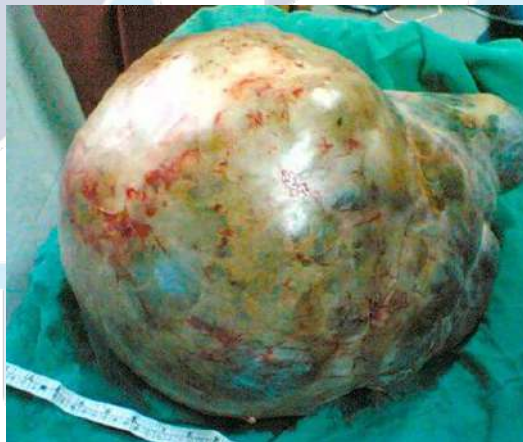- A) Stage IIIA
- B) Stage IIIB
- C) Stage IVA
- D) Stage IVB

**Correct Answer: B) Stage IIIB**

**Q.9**

**Clinical Question:**

A woman presents with abdominal distension and ascites. On examination, the abdomen is enlarged, and CA-125 levels are elevated. Imaging shows a large multicystic ovarian mass with irregular septations. What is the most likely diagnosis?



**Options:**

- A) Serous cystadenocarcinoma
- B) Granulosa cell tumor
- C) Simple serous cystadenoma
- D) Mucinous cystadenoma

**Correct Answer: A) Serous cystadenocarcinoma**

**Q.10****Clinical Question:**

A woman develops atonic postpartum hemorrhage that does not respond to initial measures and medical management. What is the next best step in management that can be done in the labour room?

**Options:**

- A) Intrauterine balloon tamponade
- B) Uterine artery ligation
- C) Internal iliac artery ligation
- D) Compression sutures

**Correct Answer: A) Intrauterine balloon tamponade**

**Q.11****Clinical Question:**

A primigravida undergoing vaginal delivery develops shoulder dystocia after delivery of the fetal head. Which of the following is the correct sequence of maneuvers used in its management?

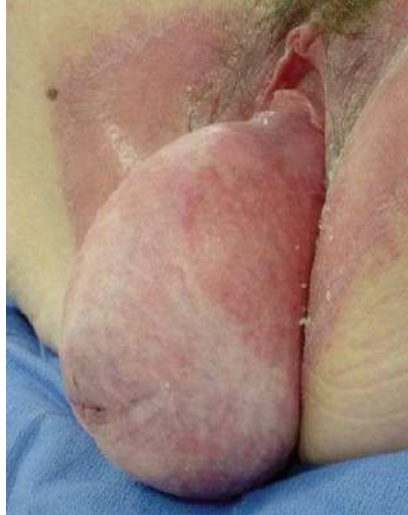**Options:**

- A) McRoberts → Rubin → Gaskin → Zavanelli
- B) Zavanelli → McRoberts → Gaskin → Rubin
- C) Rubin → McRoberts → Gaskin → Zavanelli
- D) Gaskin → Rubin → McRoberts → Zavanelli

**Correct Answer: A) McRoberts → Rubin → Gaskin → Zavanelli**

**Q.12****Clinical Question:**

A woman, P2L2, with a history of difficult vaginal deliveries conducted by an untrained attendant, now presents with the complaint of "something coming out of her vagina." On examination, the finding is as shown in the image below. Injury to which of the following ligaments is most likely responsible for this condition?



**Options:**

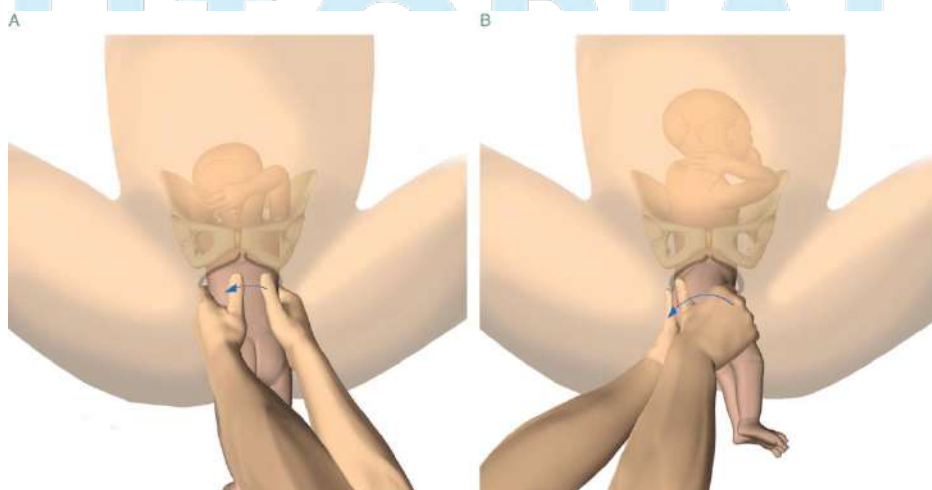
- A) Sacrospinous ligament
- B) Mackenrodt's ligament
- C) Broad ligament
- D) Round ligament

**Correct Answer: B) Mackenrodt's ligament**

**Q.13**

**Clinical Question:**

During an assisted breech delivery, the attending identified winging of the scapula and performed the following manoeuvre. Identify this.



**Options:**

- A) Lovset maneuver
- B) Burn-Marshall maneuver

[Click Here to Explore More ObGyn PYQs](#)

- C) Mauriceau-Smellie-Veit maneuver
- D) Pinard's maneuver

**Correct Answer: A) Lovset maneuver**

**Q.14**

**Clinical Question:**

A 55-year-old post-menopausal woman presents to the OPD for a routine BP checkup. Her BP was 170/100 mmHg. She also complains of a blood-stained discharge per vagina. What is the next best step in management?

**Options:**

- A) Reassure her that some discharge is normal at this age
- B) Immediate referral to a cardiologist before any further evaluation
- C) Immediate pelvic examination, transvaginal sonography (TVS), and Pap smear
- D) Start antihypertensive medication and observe for 1 week

**Correct Answer: C) Immediate pelvic examination, transvaginal sonography (TVS), and Pap smear.**

**Q.15**

**Clinical Question:**

A 46-year-old nulliparous woman presents with delayed cycles and heavy bleeding for the past 1 year. Transvaginal ultrasonography reveals an endometrial thickness of 18 mm. What is the next best step in management?

**Options:**

- A) Start combined oral contraceptive pills
- B) Schedule hysterectomy
- C) Wait and watch for 6 months
- D) Perform endometrial biopsy

**Correct Answer: D) Perform endometrial biopsy**

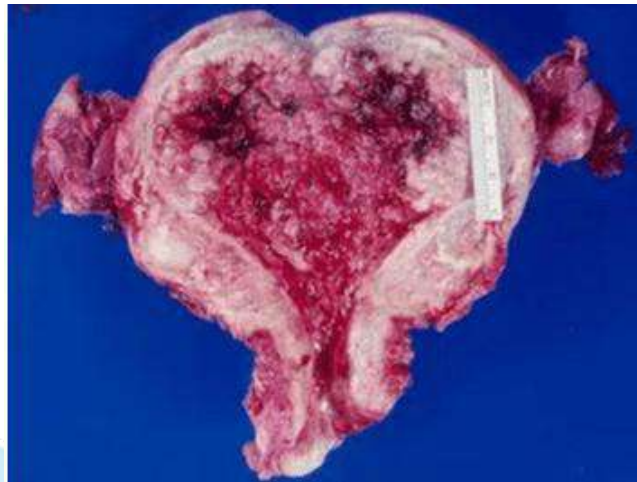
**Q.16**

**Clinical Question:**

A 65-year-old postmenopausal female presents with a chief complaint of vaginal bleeding for the past three months. She undergoes a hysterectomy, and the gross specimen is shown

[Click Here to Explore More ObGyn PYQs](#)

below. Based on the image and clinical scenario, which of the following is the most likely diagnosis?



**Options:**

- A) Endometrial cancer
- B) Fibroid
- C) Endometriosis
- D) Adenomyosis

**Correct Answer: A) Endometrial cancer**

**Q.17**

**Clinical Question:**

A woman presents for her first antenatal visit and reports that her LMP was approximately 2 months ago. Which ultrasound parameter is the most accurate for dating the pregnancy at this stage?

**Options:**

- A) Biparietal Diameter (BPD)
- B) Crown-Rump Length (CRL)
- C) Femur Length (FL)
- D) Abdominal Circumference (AC)

**Correct Answer: B) Crown-Rump Length (CRL)**

**Q.18**

**Clinical Question:**

A primigravida at 37 weeks presents with decreased fetal movements for one day. A Nonstress Test (NST) showed one acceleration in 20 minutes and no decelerations. What is the next step in management?

**Options:**

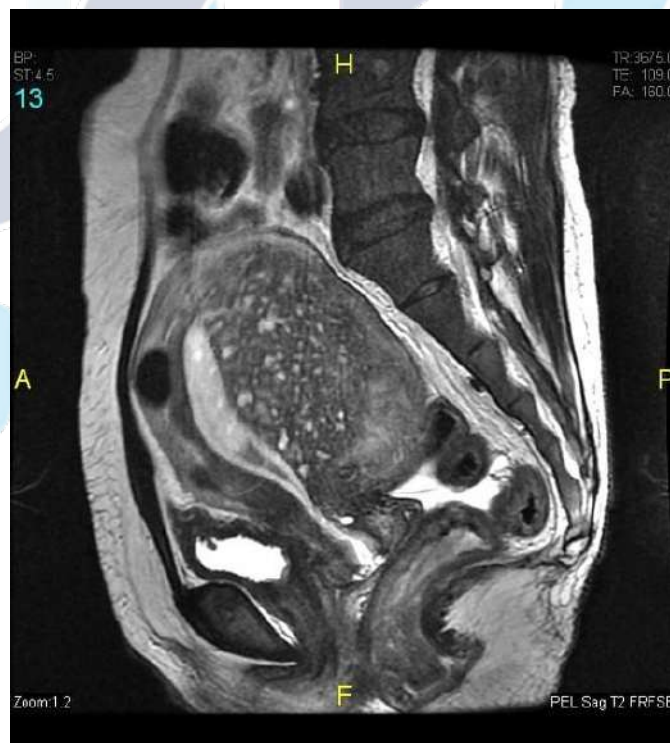
- A) Continue NST for 40 minutes
- B) Induce labour immediately
- C) Emergency LSCS
- D) Instrumental delivery

**Correct Answer: A) Continue NST for 40 minutes**

**Q.19**

**Clinical Question:**

A 42-year-old woman presents with chronic lower abdominal pain and dysmenorrhea. MRI is as shown. What is the most likely diagnosis?



**Options:**

- A) Intramural fibroid
- B) Adenomyosis
- C) Endometrial carcinoma

[Click Here to Explore More ObGyn PYQs](#)

D) Endometriosis

**Correct Answer: B) Adenomyosis**

**Q.20**

**Clinical Question:**

A pregnant female gives a history of toxoplasma infection 5 years ago and currently tests positive for IgG antibodies. On examination, lymphadenopathy is noted. What is the next step in management?

**Options:**

- A) Reassure and continue the pregnancy
- B) Carry out an MTP
- C) Counsel her about the potential teratogenic effects of the infection
- D) Treat the female for toxoplasmosis

**Correct Answer: A) Reassure and continue the pregnancy**

**For more PYQs – Sign up on the DocTutorials App Now!**

**Website:** <https://www.doctutorials.com/plans>

**Play store:** <https://zcu.io/3jPK>

**App store:** <https://apple.co/2Zmm9jr>

# TUTORIALS

[Click Here to Explore More ObGyn PYQs](#)